

Original Article

Microneedling for atrophic post-acne scars: is it effective? A prospective study of 36 cases at a tertiary care centre

微針對萎縮性痤瘡後疤痕是否有效？在一所第三級醫療中心的 36 個病例的前瞻性研究

K Varma, S Bhargava, U Kumar

Atrophic acne scars, the most common sequel of acne vulgaris are always a challenge to treat. Though many new modalities including chemical peels, soft tissue augmentation, lasers (non-ablative, ablative and fractional), subcision and radio frequency have been used. Microneedling stands out to be the cheapest, easiest and most efficacious modality in Indian skin type. We evaluated its effectiveness as the sole modality for treating atrophic acne scars. We found that there was an overall improvement in 91.8% patients by at least one grade. There were no serious complications except transient pain, erythema and oedema for 3-6 hours.

萎縮性痤瘡疤痕是尋常痤瘡治療上最常見的後續挑戰。雖然現今一眾新式療法如化學換膚、軟組織增大、激光如非剝離性、剝離性和分段式、皮下分離和射頻等都有效用，但微針在印度皮膚類型中因其最便宜、最簡單及高成效而排眾而出。我們評估其作為萎縮性痤瘡疤痕的單一治療方法的有效性。我們發現91.8%的患者至少有一個級別的總體改善。除了為時三至六小時的短暫疼痛、紅斑和水腫，沒有嚴重併發症發生。

Keywords: Acne, Atrophic, Dermaroller, Microneedling, Scars

關鍵詞：痤瘡、萎縮性、微針滾輪、微針、疤痕

Introduction

Atrophic post-acne facial scarring-the most common complication of acne vulgaris, is always a challenge for dermatologists across the globe.

Department of Dermatology, R.D. Gardi Medical College, Ujjain, India

K Varma, MD, DD & VD
S Bhargava, MD, MBBS
U Kumar, MD, MBBS

Correspondence to: Dr. S Bhargava
32, Varruchi Marg, Freeganj, Ujjain (M.P.) 456010, India

The resulting appearance can lead to anxiety, reduced self-esteem, depression and tendency to commit suicide.¹ Post-acne scars have been categorised into many morphological types like atrophic, hypertrophic and keloidal scars. Atrophic scars due to loss of dermal collagen are further classified into ice-pick, rolling and boxcar scars.² Among various treatment modalities, pharmacological management includes systemic and topical retinoids while procedural modalities include dermabrasion, chemical peels, soft tissue augmentation, subcision, punch excision, microneedling, non-ablative and ablative laser resurfacing, fractional laser resurfacing and

fractional radio frequency. Though dermabrasion and laser resurfacing using CO₂ and Er:YAG lasers can significantly improve facial atrophic scars, daily activities may be affected in the post-treatment period.³ Contrary to this, modalities like microdermabrasion and non-ablative laser resurfacing lead to a lower response as compared with the above modalities, but have better tolerability and shorter downtime.⁴ Newer modalities like microneedling therapy have been employed in past few years to overcome these short-comings. The roller is a drum-shaped device, developed by Fernandes which has very fine protruding stainless steel needles of 0.25-3 mm in length (Figure 1).⁵ Each needle of the dermapen

or dermaroller punctures the skin and forms a channel or micro-wound. The microtraumatisation leads to an activation of the healing cascade along with activation of growth factors and cell proliferation leading to increased synthesis and deposition of collagen-elastin complex. There is successive transformation of collagen III to collagen I with neoangiogenesis and thus accelerated scar remodelling.⁶ This leads to reduction of scars and skin rejuvenation characterised by improved firmness, texture and hydration of skin.

Material and methods

A total of 40 cases with atrophic post-acne scars attending the dermatology outpatient department of a tertiary care hospital were recruited for the present study which aimed to establish the efficacy of microneedling for atrophic facial acne scars. Only patients aged 18 years and above with Grade 2 to Grade 4 atrophic scarring were enrolled. Cases with active acne, active bacterial or viral infection, keloid tendency, diabetes, pregnant females, lactating mothers, who were taking oral steroid or anti-coagulant therapy were excluded from the study. Informed written consent was obtained from all the patients. All enrolled patients with atrophic scars were graded according to Goodman and Baron's acne scar grading system.⁷ Digital photographs of the affected part

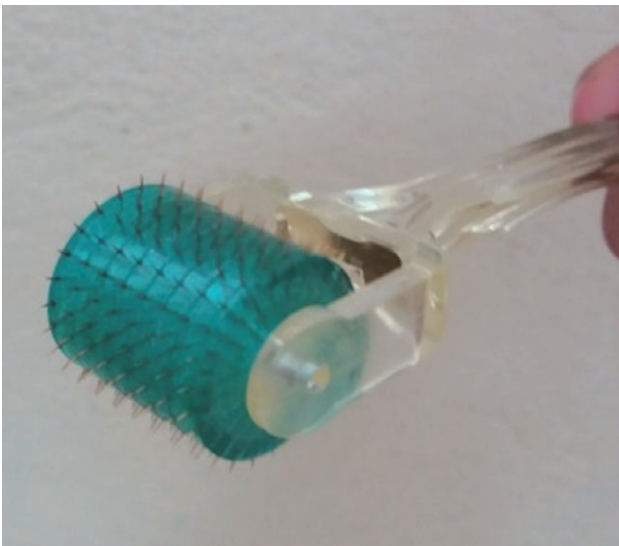

Figure 1. A dermaroller with 1.5 mm long needles.

Table 1. Grading of atrophic scars as per Goodman and Baron's acne scar grading system

Grade 1	Erythematous, hyper- or hypopigmented flat marks. No problem of contour like other scar grades.
Grade 2	Mild atrophic or hypertrophic scars that may not be obvious at social distances of ≥ 50 cm and may be covered adequately by makeup.
Grade 3	Moderate atrophic or hypertrophic scarring that is obvious at social distances ≥ 50 cm, is not covered easily by makeup and still able to be flattened by manual stretching of the skin (if atrophic).
Grade 4	Severe atrophic or hypertrophic scars that are obvious at social distances > 50 cm, is not covered easily by makeup and is not able to be flattened by manual stretching of the skin.

of face were taken at baseline. The area of treatment was anaesthetised 45-60 minutes before the treatment with a topical anaesthetic agent. Microneedling procedure using dermaroller with 1.5 mm long needles was performed in four different directions with uniform bleeding points as the endpoint. Patients were reviewed after one week for any side effects. A total of four sessions at intervals of four weeks were performed. Scar grading was observed before the procedure, after three treatment sessions and three months post-treatment using Goodman and Baron's acne scar grading system,⁷ and repeat photographs were taken and compared. An improvement of scar grading by two grades or more was labelled as 'excellent' improvement whereas 'good' response signified an improvement by a single grade.

Results

Among 36 cases who completed the study, the age ranged from 19 years to 35 years (mean age

24.8 years). There were 20 females and 16 males with a female: male ratio of 1:1.25. All cases had a combination of various types of atrophic scars: ice-pick, rolling and boxcar. At the beginning of the treatment, there were 18 (50%) Grade III scars, 14 (38.88%) Grade IV scars and 4 (11.11%) Grade II scars. Four patients did not complete the treatment. After three sessions of microneedling four weeks apart, the proportion of patients with Grade 2 scars had increased significantly from 11% to 38% ($Z=2.75$, $p=0.006$), while the proportion of patients with Grade 3 scars was almost the same ($Z=0.235$, $p=0.81$) because nine cases with Grade 4 had improved to Grade 3 (Table 2). The proportion of patients with Grade 4 decreased significantly from 39% to 14% ($Z=2.4$, $p=0.01$).

Three months after the final treatment, the proportion of Grade 1 and Grade 2 patients increased significantly from 0 to 13% ($Z=2.31$, $p=0.02$) and 11% to 53% ($Z=3.79$, $p=0.00$) respectively (Table 3). The proportion of patients

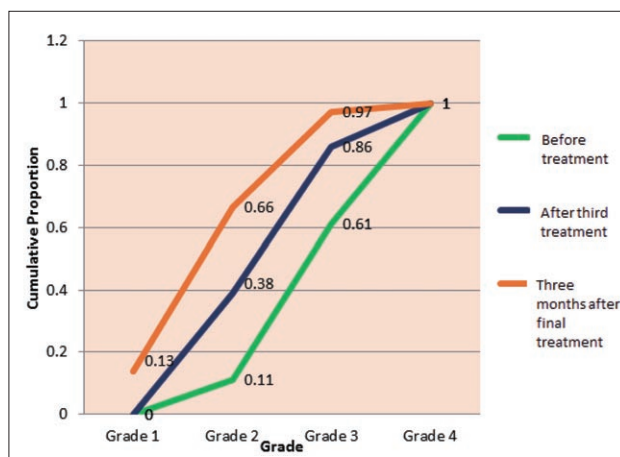
Table 2. Comparison of proportions according to grades before the treatment and after three treatment sessions

Grade	No. of patients before the treatment	No. of patients after 3 sittings	'Z' value	'p' value
Grade 1	0	0	0	0
Grade 2	4	14	2.72	0.006
Grade 3	18	17	0.235	0.81
Grade 4	14	5	2.401	0.01

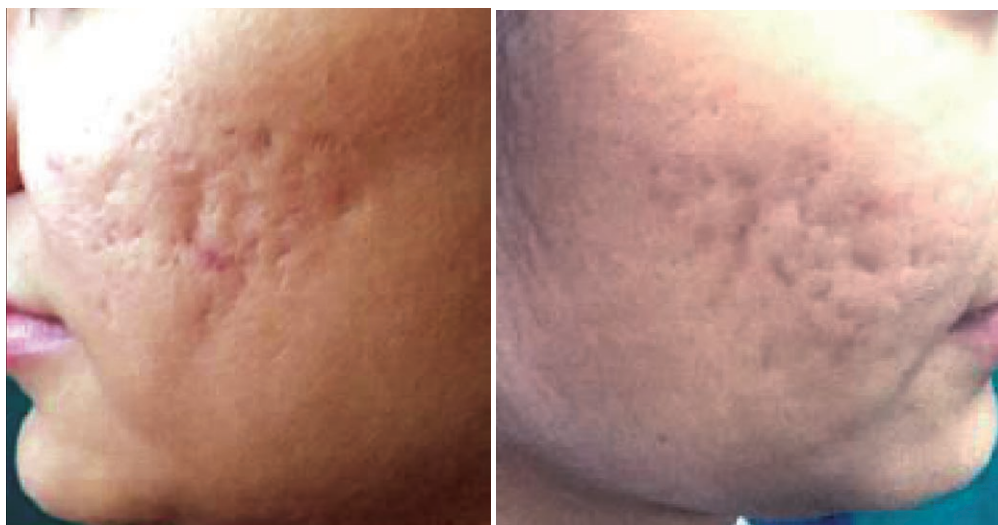Table 3. Comparison of proportions according to grades before treatment and 3 months after the final treatment session

Grade	No. of patients before the treatment	No. of patients after 3 months of final sitting	'Z' value	'p' value
Grade 1	0	5	2.31	0.02
Grade 2	4	19	3.79	0.00
Grade 3	18	11	1.68	0.09
Grade 4	14	1	3.47	0.00

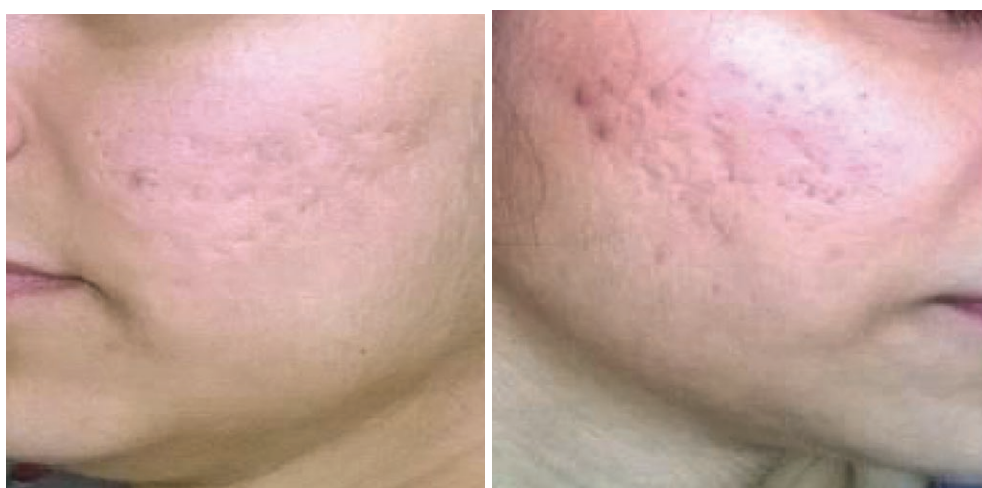with Grade 4 declined from 39% to 3% ($Z=3.47$, $p=0.00$) without significant change in proportion of patients with Grade 3 due to improvement of 10 cases with Grade 4 overall to Grade 3. The cumulative proportion of patients in different grades before treatment, after three sessions and after three months post treatment is illustrated in Graph 1. There were five cases (13.8%, 3 cases of Grade 4 improved to Grade 2 and two cases of Grade 3 improved to Grade 1) with an 'excellent' response (Figures 2-7). The majority (28) of patients had 'good' response (improvement by single Grade) constituting to 77.78% (10 cases with Grade 4 improved to Grade 3, 15 cases with Grade 3 improved to



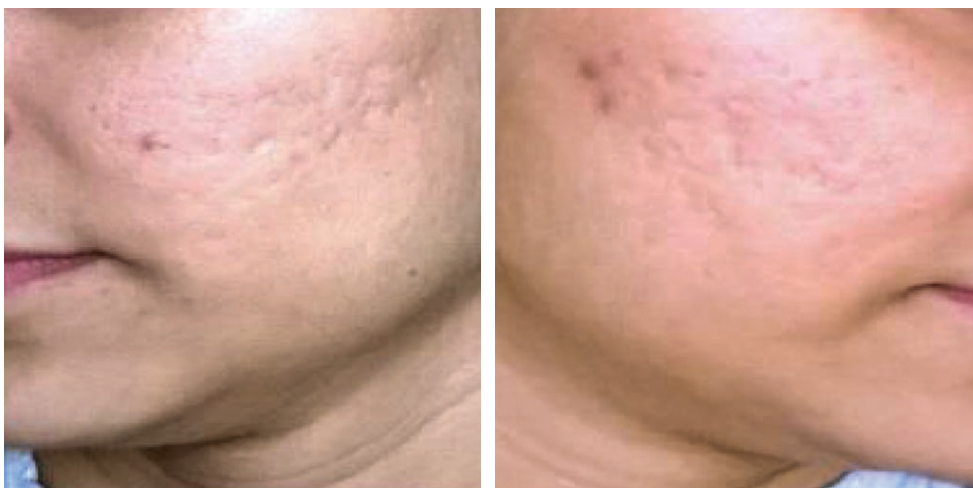Graph 1. Cumulative proportion of patients with different scar grading before the treatment, after 3 sessions and 3 months post treatment.



Figures 2 and 3. Left and right cheek of a patient with Grade 4 scarring before the treatment.



Figures 4 and 5. Left and right cheek of a patient who improved to Grade 3 from Grade 4 after 3 sessions of microneedling.



Figures 6 and 7. Left and right cheek of a patient who improved to Grade 2 from Grade 4 after completing treatment, grading was assessed three months post treatment.

Grade 2 and three cases with Grade 2 improved to Grade 1) whereas three cases (8.33%, 1 case each of Grade 4, 3 and 2) did not show any improvement. There was an overall improvement in 91.8% of cases.

Though the microneedling technique stimulates collagen formation in the dermis, it also injures the epidermis and the dermal vessels. Hence following haemostasis of the bleeding points post treatment, there was erythema along with slight oedema over the treated part of the face in all the patients. The erythema lasted for 3-6 hours in the majority of patients. The injury to the epidermis was controlled and did not cause any dyspigmentation. There were no serious side effects of the procedure in any of the subjects.

Discussion

Acne scar management has been a challenging task and focus of interest for dermatologists for several decades. Remarkable advances have been made to revise atrophic acne scars namely ice pick, rolling or superficial, and boxcar scars. In the present era, ablative lasers such as CO₂ and Er:YAG have shown an efficacy of 40-90% but unfortunately are associated with erythema for almost three months,⁸ while non-ablative lasers

such as Nd:YAG and diode lasers have a lower efficacy of 20-40%.⁹ Recently, ablative fractional lasers have been introduced which have a shorter downtime than ablative CO₂ lasers and reasonably good results.¹⁰ There is a statistically significant increase in collagen types I, III, and VII and newly synthesised collagen, while total elastin was significantly decreased after treatment.¹¹ In the present study, an attempt has been made to prove the efficacy of microneedling using dermaroller for atrophic acne scars. This is a cheap and an effective modality with a downtime of only few hours. We observed that females outnumbered the males with a male: female ratio of 1:1.25. Females were more concerned about undergoing treatment for acne scars as in other studies.¹²⁻¹⁵ We performed microneedling four times at four week intervals whereas other authors performed three sessions four weeks apart.^{12,15} Dogra¹³ and Alam¹⁴ performed five and three sessions respectively with intervals of four and two weeks respectively. In our study, the scar grading was assessed after three sessions and also three months post-treatment. Dogra, Majid and Fabbrocini evaluated the grading of scars after one month, two months and 13 months respectively after the final session whereas in one of the study, follow-up was for six months and grading was assessed twice post treatment at three and six months.¹⁴ The patient recovery time in our

study was minimal which is in line with other studies. There were two studies which reported post-inflammatory hyperpigmentation after the microneedling procedure in one and five patients respectively.^{12,13} In the present study, 91.8% (33 out of 36) cases showed either good or excellent improvement in scar grading. Studies done by Dogra and Majid also showed improvement by at least a single grade in 86.6% (26 of 30) and 94.4% (34 of 36) cases respectively.

Conclusion

Microneedling is a low cost, well-tolerated, and simple day care procedure with minimal side effects and complications. It not only improves atrophic scars but also has beneficial effects on skin texture. At least 8-12 weeks is required for percutaneous collagen induction to occur and show aesthetic improvement in acne scar appearance. An excellent to good response can be found in the majority of patients with Grade 4, 3 and 2 acne scarring. Apart from slight oedema and erythema lasting for 3-6 hours, there were no serious side effects.

References

1. Saitta P, Keehan P, Yousif J, Way BV, Grekin S, Brancaccio R. An update on the presence of psychiatric comorbidities in acne patients, Part 2: Depression, anxiety, and suicide. *Cutis* 2011;88:92-7.
2. Jacob CI, Dover JS, Kaminer MS. Acne scarring: a classification system and review of treatment options. *J Am Acad Dermatol* 2001;45:109-17.
3. Alster TS. Cutaneous resurfacing with CO2 and erbium: YAG lasers: Preoperative, intraoperative and postoperative considerations. *Plast Reconstr Surg* 1999; 103:619-32.
4. Cohen BE, Brauer JA, Geronemus RG. Acne scarring: A review of available therapeutic lasers. *Lasers Surg Med* 2016;48:95-115.
5. Fernandes D. Percutaneous collagen induction: an alternative to laser resurfacing. *Aesthet Surg J* 2002; 22:307-9.
6. Šuca H, Zajček R, Vodsoň Z. Microneedling – A form of collagen induction therapy - our first experiences. *Acta Chir Plast* 2017;59:33-6.
7. Goodman GJ, Baron JA. Post acne scarring: A qualitative global scarring grading system. *Dermatol Surg* 2006; 32:1458-66.
8. Jordan R, Cummins C, Burls A. Laser resurfacing of skin for improvement of acne scarring: A systematic review of evidence. *Br J Dermatol.* 2000;142:413-23.
9. Maluki AH, Mohammad FH. Treatment of atrophic facial scars of acne vulgaris by Q-Switched Nd:YAG (Neodymium: Yttrium-Aluminum-Garnet) laser 1064 nm wavelength. *J Cosmet Laser Ther* 2012;14: 224-33.
10. You HJ, Kim DW, Yoon ES, Park SH. Comparison of four different lasers for acne scars: Resurfacing and fractional lasers. *J Plast Reconstr Aesthet Surg* 2016; 69:87-95.
11. El-Domyati M, Barakat M, Awad S, Medhat W, El-Fakahany H, Farag H. Microneedling Therapy for Atrophic Acne Scars: An Objective Evaluation. *J Clin Aesthet Dermatol* 2015;8:36-42.
12. Majid I. Microneedling therapy in atrophic facial scars: an objective assessment. *J Cutan Aesthet Surg* 2009;2: 26-30.
13. Dogra S, Yadav S, Sarangal R. Microneedling for acne scars in Asian skin type: an effective low cost treatment modality. *J Cosmet Dermatol* 2014;13:180-7.
14. Alam M, Han S, Pongprutthipan M, Disphanurat W, Kakar R, Nodzanski M, et al. Efficacy of a needling device for the treatment of acne scars: a randomized clinical trial. *JAMA Dermatol* 2014;150:844-9.
15. Fabbrocini G, De Vita V, Monfrecola A, De Padova MP, Brazzini B, Teixeira F, et al. Percutaneous collagen induction: an effective and safe treatment for post-acne scarring in different skin phototypes. *J Dermatolog Treat* 2014;25:147-52.