

Occasional review

The relevance of the Lewy body to the pathogenesis of idiopathic Parkinson's disease

W R G GIBB, A J LEES

From the Department of Neuropathology, National Hospitals for Nervous Diseases, Maida Vale, London, UK

SUMMARY The Lewy body is a distinctive neuronal inclusion that is always found in the substantia nigra and other specific brain regions in Parkinson's disease. It is mainly composed of structurally altered neurofilament, and occurs wherever there is excessive loss of neurons. It occurs in some elderly individuals and rarely in other degenerative diseases of the central nervous system. In 273 brains of patients dying from disorders other than Parkinson's disease, the age-specific prevalence of Lewy bodies increased from 3.8% to 12.8% between the sixth and ninth decades. Associated pathological findings suggest that these cases of incidental Lewy body disease are presymptomatic cases of Parkinson's disease, and confirm the importance of age (time) in the evolution of the disease. In view of the common and widespread occurrence of this disorder we propose that endogenous mechanisms operating in early life may be more important than environmental agents in the pathogenesis of Lewy bodies and Parkinson's disease.

Neuronal inclusions called Lewy bodies are present in many surviving cells of the substantia nigra in all cases of Parkinson's disease fulfilling the UK Parkinson's Disease Society Brain Bank clinical diagnostic criteria (table 1), if alternative Parkinsonian disorders are identified and excluded by pathological examination. Lewy bodies therefore provide a diagnostic marker and are as essential for the pathological diagnosis as the specific distribution of cell loss. The absence of Lewy bodies in even one bilateral 7 μ m section of substantia nigra excludes Parkinson's disease.¹ Reports of Lewy bodies in individuals without Parkinsonian features suggest a presymptomatic phase of the disease (incidental Lewy body disease).² Less commonly dementia^{3,4} and autonomic failure,⁵ due to cell loss and Lewy body formation in extranigral sites, complicate Parkinson's disease, or rarely occur alone. These other manifestations of the Lewy body-Parkinson's disease spectrum encourage the inclusive pathological term of idiopathic Lewy body disease (table 2).

In recent years it has emerged that a small group of

rare disorders or rare variants of common disorders are also sometimes associated with Lewy bodies in the nervous system, usually in some of the same areas affected in idiopathic Lewy body disease (table 2). These differ, however, because most are familial, occur at a young age and are associated with additional pathological lesions. In contrast to Parkinson's disease Lewy bodies are not invariably present; for example they are reported in only 10–15% of cases of Hallervorden-Spatz disease.

IDIOPATHIC LEWY BODY DISEASE

Distribution of Lewy bodies

In Parkinson's disease the distribution of Lewy bodies is fairly specific and only certain medium to large-sized monoaminergic and cholinergic neurons are involved. In addition, the entire autonomic nervous system is affected,^{12–14} from the Edinger-Westphal nucleus, to the salivatory nuclei, dorsal vagal nucleus, the intermediolateral nucleus, and sympathetic and parasympathetic ganglia. In Parkinson's disease the distribution of Lewy bodies is generalised, they can easily be found in neurons of the substantia nigra, locus coeruleus, dorsal vagal nucleus, nucleus basalis of Meynert and hypothalamus, and sometimes in other sites such as the cerebral cortex, thalamus and autonomic ganglia. The selection of specific cell pop-

Address for reprint requests: Dr W R G Gibb, National Hospitals for Nervous Diseases, Maida Vale, London W9 1TL, UK.

Received 25 September 1987 and in revised form 5 February 1988.
Accepted 16 February 1988

Table 1 *UK Parkinson's Disease Society Brain Bank clinical diagnostic criteria*

STEP 1. Diagnosis of PARKINSONIAN SYNDROME.

BRADYKINESIA (slowness of initiation of voluntary movement with progressive reduction in speed and amplitude of repetitive actions).

And at least one of the following:

- a. muscular rigidity
- b. 4–6 Hz rest tremor
- c. postural instability not caused by primary visual, vestibular, cerebellar or proprioceptive dysfunction.

STEP 2. Exclusion criteria for Parkinson's disease.

history of repeated strokes with stepwise progression of Parkinsonian features

- history of repeated head injury
- history of definite encephalitis
- oculogyric crises
- neuroleptic treatment at onset of symptoms
- more than one affected relative
- sustained remission
- strictly unilateral features after three years
- supranuclear gaze palsy
- cerebellar signs
- early severe autonomic involvement
- early severe dementia with disturbances of memory, language and praxis
- Babinski sign
- presence of a cerebral tumour or communicating hydrocephalus on CT scan.
- negative response to large doses of levodopa (if malabsorption excluded)
- MPTP exposure

STEP 3. Supportive prospective positive criteria for PARKINSON'S DISEASE. Three or more required for diagnosis of definite Parkinson's disease.

- unilateral onset
- rest tremor present
- progressive disorder
- persistent asymmetry affecting the side of onset most
- excellent response (70–100%) to levodopa
- severe levodopa-induced chorea
- levodopa response for 5 years or more
- clinical course of 10 years or more

ulations (pathoklisis)¹⁵ and the apparent absence of transynaptic or retrograde degeneration is one of the main characteristics of the disease process. Cell loss is documented for most locations in which Lewy bodies occur and consequently the Lewy body is considered a marker of neuronal degeneration.

Structure and composition of the Lewy body

In pigmented cells of the substantia nigra and locus coeruleus the Lewy body is usually eosinophilic, intracytoplasmic, round and 5–25 μm in diameter. Most consist of a central body surrounded by a pale-staining halo. Classical, but less common forms also have a darker centre (core) and/or darker rings (laminae) (fig 1a). Lewy bodies also exist within nerve cell processes and free in the neuropil when released from a dying cell. Inclusions in nerve cell processes are common in the dorsal vagal nucleus and sympathetic ganglia, where they are frequently elongated or complex in shape. Ultrastructurally the body is formed from aggregated filament, 7–15 nm in diameter,

arranged in a radially orientated or haphazard formation.¹⁶ The deep eosinophilia of the core and halo is due to greater packing density and apparent structural degradation of filaments. Polyclonal antibodies reacting with neurofilament proteins produce homogeneous or peripheral ring-like staining of Lewy bodies in the substantia nigra and locus coeruleus.¹⁷ Similar results are obtained with monoclonal antibodies to neurofilament polypeptides^{18–21} demonstrating that at least some amino acid sequences are common to neurofilaments and Lewy bodies. The pattern of immunostaining appears to be determined by the structural arrangement of the Lewy body, the better preserved filaments showing preferential staining. This explains why cortical and some brainstem Lewy bodies stain centrally,²² while most brainstem Lewy bodies showing a central density (core) stain peripherally (fig 1, b & c). The outer part of the halo contains few filaments, mixed with other organelles, and does not stain. The potential contribution of other cytoskeletal elements to the Lewy body is under investigation.

There are other morphological changes in Parkinson's disease that mirror the distribution of Lewy bodies. One of these is the granular pale body which, in contrast to the Lewy body, is round or irregularly shaped, finely granular in texture and up to 30 μm in diameter. It fails to react with conventional histological stains including silver (fig 1d). It should be distinguished from the Lewy body, because its appearance is less specific and is mimicked by neuronal changes in a variety of disorders including

Table 2 *Classification of Lewy body diseases*

<i>Sporadic</i>	
<i>specific, generalised distribution of Lewy bodies</i>	
idiopathic* (primary) Lewy body disease	
asymptomatic (presymptomatic)	
Lewy body-Parkinson's disease	
cortical Lewy body dementia	
Lewy body-autonomic failure	
subacute sclerosing panencephalitis	
<i>Sporadic or familial</i>	
<i>specific, generalised distribution of Lewy bodies</i>	
juvenile Parkinsonian syndrome ⁶	autosomal dominant
olivopontocerebellar atrophy ⁷	autosomal dominant
Joseph disease ⁸	autosomal dominant
Hallervorden-Spatz disease ⁹	autosomal recessive or "sporadic"
ataxia-telangiectasia ¹⁰	autosomal recessive
<i>Lewy bodies only in motor neurons</i>	
motor neuron disease ¹¹	autosomal dominant or "sporadic"

*the term "idiopathic" is used here to denote that the disease is not associated with familial inheritance or other pathological lesions.

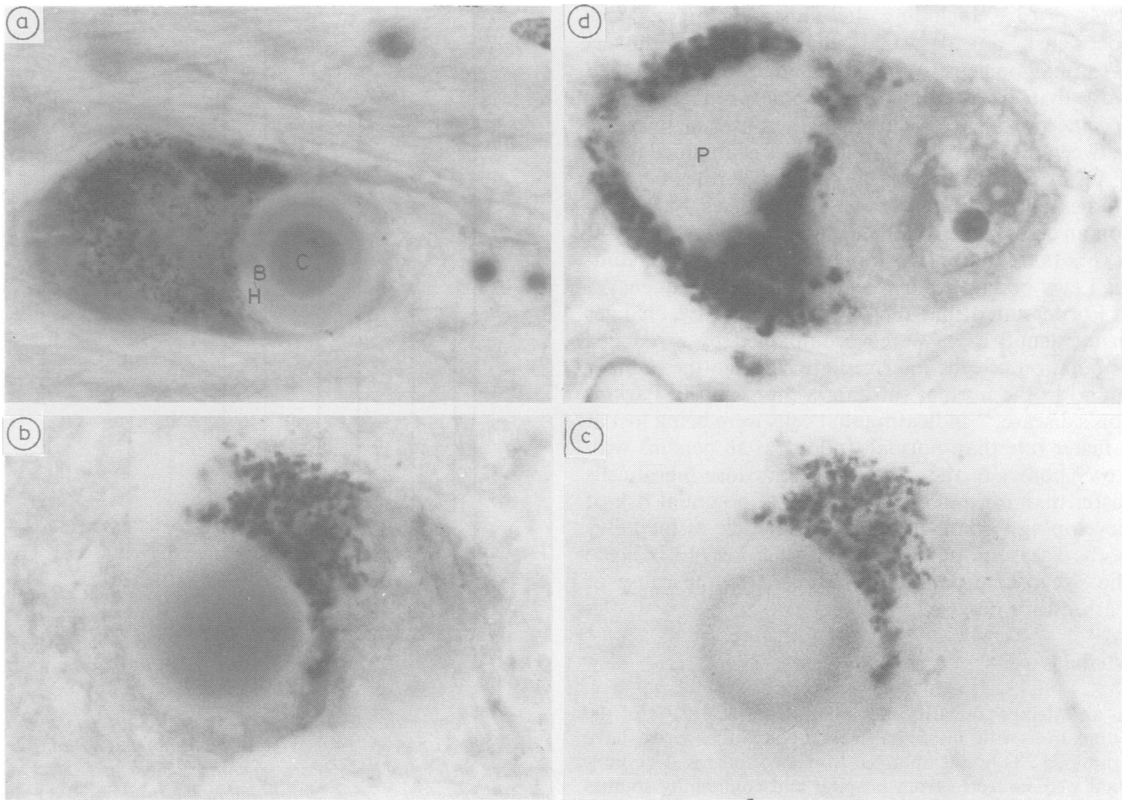


Fig 1 (a) Lewy body with core (C), body (B) and halo (H) in pigmented cell of the locus coeruleus. Haematoxylin and eosin (H&E), $\times 2625$. (b) Lewy body in the locus coeruleus stained with H&E, $\times 3360$. (c) Same Lewy body as in (b) stained only with monoclonal antibody RT97, $\times 3360$. (d) Pale body (P) in pigmented cell of the substantia nigra. H&E stain, $\times 3360$.

Pick's disease, corticobasal degeneration and even Alzheimer's disease and Steele-Richardson-Olszewski syndrome.

In view of the high degree of specificity of Lewy bodies their successful experimental induction could lead to advances in understanding the cellular abnormalities of Parkinson's disease. However, they have not been found in non-human primates and it has not been possible to induce them experimentally. Filamentous aggregations in proximal axons and perikarya are an age- or disease-related histological feature in man, but can be induced by iminodipropionitrile, aluminium, spindle poisons²³ and 1-methyl-4-phenyl-1,2,3,6-tetrahydropyridine (MPTP).^{24,25} Accumulation of neurofilament appears to be an essential abnormality in Parkinson's disease and could result from an abnormality in the structure of neurofilament, from other ingredients or from changes in the intraneuronal environment. However, the subsequent formation of the distinctive morphology of the Lewy body may be a non-specific process.

INCIDENTAL LEWY BODY DISEASE

Age-specific prevalence

In Parkinson's disease loss of substantia nigra cells probably starts long before symptoms develop; in fact an estimated 80% depletion of striatal dopamine occurs before the onset of motor symptoms.^{26,27} Even elderly patients who die early in the course of the disease from unrelated disorders show moderate degrees of cell loss. It might be anticipated therefore that nigral cell loss and Lewy bodies could be found in healthy persons without signs of Parkinson's disease.²⁸ A few studies do confirm that Lewy bodies can be found in the normal elderly population, but these differ in the source of the material and the methods employed. In one study of 400 patients from California Mental Hospitals, 172 were younger than 60 years at death, but Lewy bodies were restricted to those aged over 60 years.² Equal prevalence rates for Lewy bodies of about 12% were identified in the seventh to ninth decades, but seven of the 27 (26%) Lewy body positive cases had Parkinsonian features. The Lewy bodies occurred in the same locations as in Parkin-

son's disease, including the substantia nigra, locus coeruleus, dorsal vagal nucleus and Edinger-Westphal nucleus. When these data are combined with that from four other studies reporting age-specific prevalence a surprisingly consistent increase between the sixth and ninth decades is obtained (table 3; fig 2). Some variation in prevalence rates between studies could result from selection of early Parkinsonian cases rather than reflecting real differences, but it is notable that in the Japanese and American studies Lewy bodies occur with considerable frequency.

Forno stated that the nigral degenerative changes in incidental cases were accompanied by a reduced population of cells intermediate between the number found in the normal substantia nigra and in Parkinson's disease,³¹ indicating that cells were being lost at a faster rate than normal. Indeed, if all persons with Lewy bodies in the substantia nigra lose nigral cells faster than normal they would be at potential risk of developing Parkinson's disease. The size of the Lewy body disease population might then help to indicate the size of the population exposed to the cause of Parkinson's disease.

Methods

In an attempt to clarify the size and characteristics of the population with incidental Lewy body disease we have examined 273 brains obtained from two sources. Two hundred were collected from hospital and community sources for standard neuropathological examination and were stored in two neuropathology laboratories. The remaining 73 cases were collected for the purpose of the study by one hospital necropsy service. After fixation in formol-saline part of the substantia nigra was blocked by horizontal cuts perpendicular to the axis of the brainstem passing ventrally between the oculomotor nerve and decussation of the superior cerebellar peduncle. After routine processing and embedding in paraffin wax one unilateral section, cut at 7 µm thickness, was prepared and stained with haematoxylin and eosin (H&E). Nerve cells in the sections were methodically

Table 3 Age specific prevalence rates of incidental Lewy body disease in reported series. Lewy bodies usually located in the substantia nigra, locus coeruleus or both (see fig 2).

Study		age in years				
		50-59	60-69	70-79	80-89	90-99
Woodard, 1962	(2)	0/62	9/75	13/108	5/43	0/2
Hamada and Ishii, 1963	(29)	1/18	4/28	5/13	0/2	0/0
Hirai, 1968	(30)	0/3	1/8	3/19	2/10	0/1
Forno and Alvord, 1971	(31)	1/45	7/77	7/99	6/29	1/6
Tomonaga, 1983	(32)	1/39	8/82	10/65	5/15	1/3
Totals		3/167	29/270	38/304	18/99	2/12
percentage prevalence		1.8%	10.7%	12.5%	18.2%	16.7%

A total of 425 brains from persons younger than age 60 years were examined. Causes of death included a wide range of neuropsychiatric and systemic diseases.

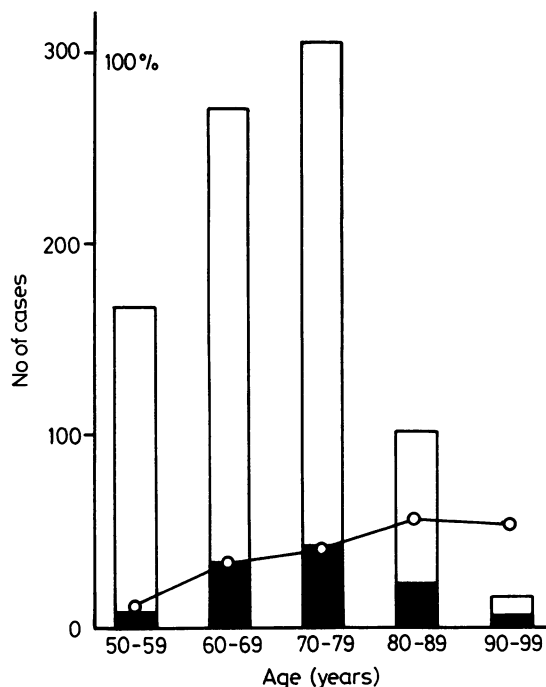


Fig 2 Age-specific prevalence rates (percent) of incidental Lewy body disease (—○—), obtained by combining data in reported series (table 3). Bars show the number of Lewy body cases (shaded area) in relation to the total cases examined in each decade.

examined by drawing around the substantia nigra and by moving in successive parallel sweeps using an eyepiece graticule. Sections were also examined from the locus coeruleus, dorsal vagal nucleus, nucleus basalis of Meynert and temporal cortex. The Lewy body was defined as an intracytoplasmic eosinophilic body with a halo.

Results

The 200 brains from neuropathology laboratories showed a variety of abnormalities, for example Huntington's chorea, Wernicke's encephalopathy, multiple sclerosis, cerebrovascular disease and trauma. Nine of

Table 4 Age-specific prevalence rates of incidental Lewy body disease in this study (see fig. 3).

age group years	retrospective series	prospective series	total
10-19	0/5	—	0/5
20-29	0/16	0/1	0/17
30-39	0/15	0/2	0/17
40-49	0/26	0/1	0/27
50-59	2/48 (4.2%)	0/5	2/53 (3.8%)
60-69	3/51 (5.9%)	0/13	3/64 (4.7%)
70-79	2/23 (8.7%)	2/20 (10.0%)	4/43 (9.3%)
80-89	2/14 (14.3%)	3/25 (12.0%)	5/39 (12.8%)
90-99	0/1	0/6	0/7
100-109	0/1	—	0/1

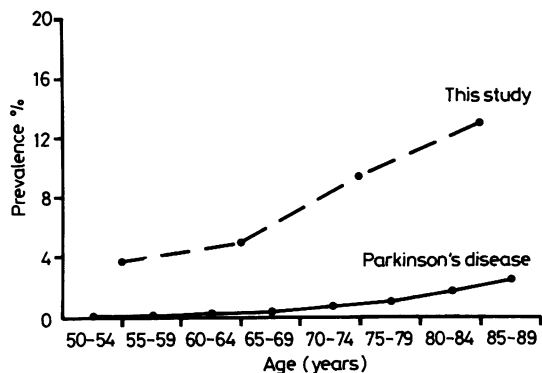


Fig 3 Graph combining pathological data on age-specific prevalence of incidental Lewy body disease and clinical data on the prevalence of Parkinson's disease in the community (percent). Data on Parkinson's disease from Mutch *et al.*³³

the brains contained Lewy bodies in the substantia nigra, none of which had moderate to severe cell loss compatible with Parkinsonian manifestations (table 4). In six of the nine cases extraneuronal melanin deposits were increased and in four cases there was mild or mild to moderate cell loss. The following diagnoses were recorded in the Lewy body positive cases; tabes dorsalis, trauma, Guillain-Barré syndrome, spinal cord angioma, multiple sclerosis, leuco-encephalitis and psychosis. In the 73 recently collected brains, five contained Lewy bodies, in all of which increased neuronal destruction and mild nigral cell loss were present. Causes of death were systemic carcinoma, cerebrovascular disease or ischaemic heart disease. The age-specific prevalence of incidental Lewy bodies progressively increased between the sixth and ninth decades (table 4, fig 3), without major differences between the two series. The site of earliest and most severe damage to the substantia nigra was always identified as the middle to lateral (or ventrolateral) region (fig 4), which is most severely affected in Parkinson's disease. Nine of the 14 incidental cases also showed destruction and loss of nigral cells of a severity intermediate between normal and Parkinson's disease. Other nuclei such as the locus coeruleus and nucleus basalis of Meynert were also involved, indicating that both the intranigral and regional distribution of lesions was identical to that in Parkinson's disease, only the severity of nigral nerve cell loss being less.

Discussion

The prevalence of Lewy bodies in this study confirms the age-related rise identified by combining published data (table 3), although the rates were lower, on average by 3.2% per decade. The figure of 3.8% in the

Table 5 Evidence that incidental Lewy body disease corresponds to presymptomatic Parkinson's disease.

—biochemical evidence for presymptomatic phase
—cases of drug-induced Parkinsonian syndrome with temporary remission on drug withdrawal, and post-mortem finding of Lewy bodies ³⁴
—progressive cell degeneration occurring at a faster rate than normal
—cell loss intermediate between "controls" and Parkinson's disease
—identical neuronal morphology
—earliest damage to middle to lateral part of substantia nigra, corresponding to that part most damaged in Parkinson's disease ³⁵
—same extranigral distribution of Lewy bodies

50s may be an overestimate and a figure more in line with that of 1.8% in reported studies (table 3) is suggested. In these studies over 140 brains of persons in their 40s were examined suggesting that the prevalence for Lewy bodies in this decade is less than 0.7%.

These observations conform to the hypothesis that incidental Lewy body cases have the same progressive pathology as that seen in Parkinson's disease (table 5). In Parkinson's disease the rate of cell destruction is remarkably constant between cases and occurs at a modest rate as suggested by the proportion of degenerating cells, quantity of extraneuronal melanin and severity of gliosis.¹² Nevertheless, some incidental Lewy body cases could represent preclinical cases of Parkinson's disease with a substantially slower rate of progression, although the indistinguishable morphological changes suggest that the basic pathogenetic mechanisms are similar.

A recent community survey of Parkinson's disease in Aberdeen showed that the age-specific prevalence rises to 1.9% in persons aged over 85 years.³³ A comparison of this clinical study and our pathological data shows roughly parallel trends with incidental Lewy body disease occurring 5–20 times more commonly than Parkinson's disease (fig 3). In view of histological evidence of comparable rates of disease progression between cases, the latent phase of up to 30 years between equivalent prevalence rates of incidental Lewy body disease and Parkinson's disease (about 2% for incidental Lewy body disease in the fifties and 2% for Parkinson's disease in the eighties), suggests a long preclinical period. This is consistent with biochemical data indicating loss of about 80% of striatal dopamine by the time of onset of symptoms.^{26,27} If the mean age of onset of Parkinson's disease is taken as 60 years then it would be possible for histological changes to start as early as 25–35 years of age. In Parkinson's disease presenting in the third and fourth decades histological changes would start considerably before this.

These findings have important implications for the aetiology and prevention of Parkinson's disease. The failure of rates of incidental Lewy body disease to

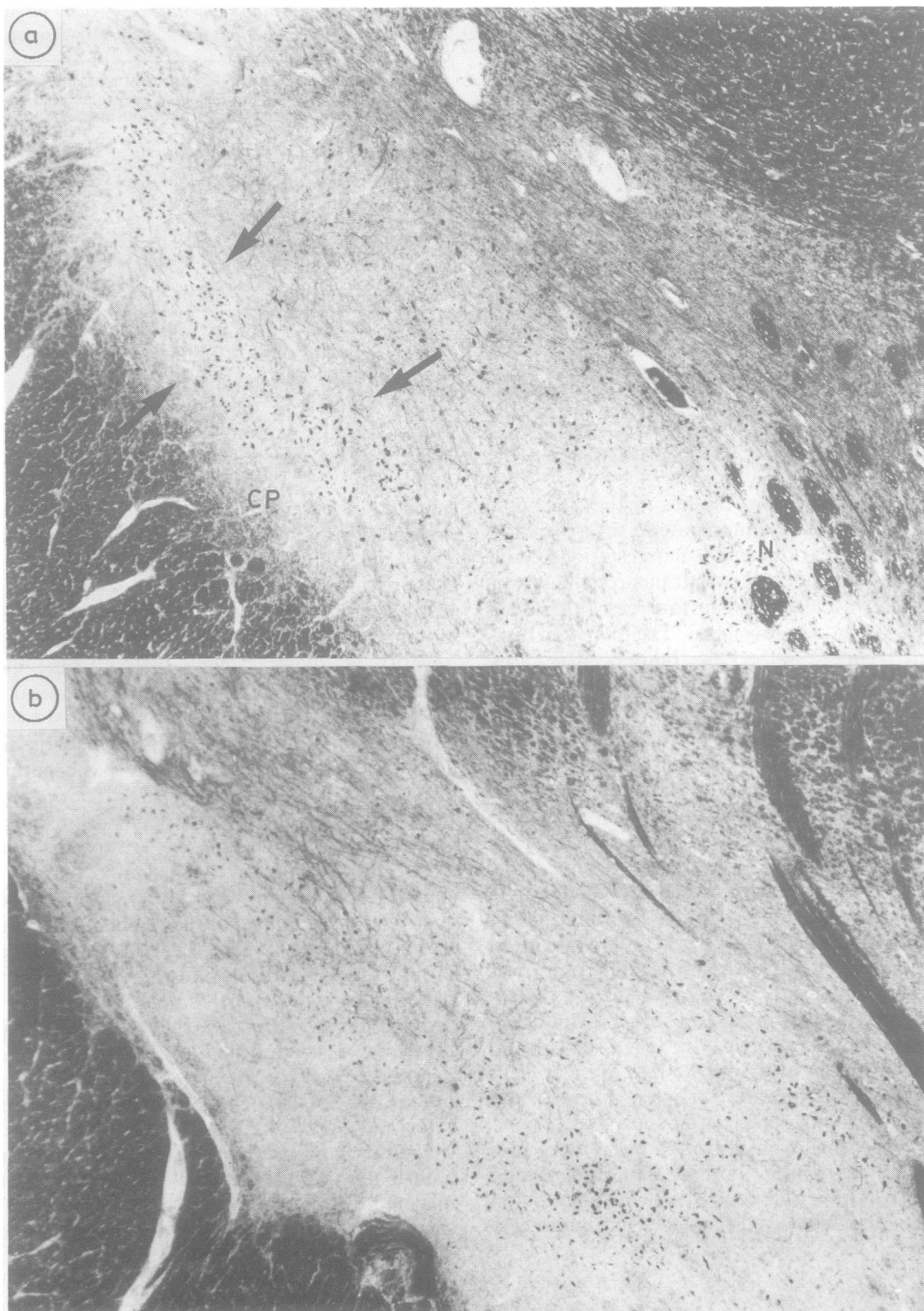


Fig 4 (a) Horizontal 7 μm -thick section of a healthy substantia nigra at the level of exit of the third nerve (N) lying medially, and the cerebral peduncle (CP) lying antero-laterally. The ventrolateral part of the substantia nigra zona compacta is shown with arrows. Kluver-Barrera, $\times 58$. (b) Similar section from a case of incidental Lewy body disease with fewer cells in the ventrolateral part. Kluver-Barrera, $\times 58$.

decline in late age conflicts with many, but not all, epidemiological studies of Parkinson's disease.³⁶ It also suggests that the size of the population exposed at an earlier age to the pathogenetic factors for Lewy body disease is unknown. A prevalence of Lewy body disease over 1 in 10 of the population in their ninth decade and a progressive increase with time (age) implies that the size of this affected population may be considerable. Much of the current epidemiological evidence on prevalence rates of Parkinson's disease show rates which are approximately stable in time and between many of the different geographical locations examined. The cause of a disease to which over 10% of the population are exposed worldwide may therefore not be a single, common environmental factor.³⁷ In addition the probable exclusion of genetic³⁸ factors for the cause of Parkinson's disease suggests that aetiological factors independent of simple environmental and genetic causes should be considered. These data do not however exclude the possibility that a common and universal environmental factor might contribute to the cause. The evidence linking normal ageing with Parkinson's disease is slim even if one considers age-related cell loss in addition to a diminished buffer reserve, which might be sustained in early life or represent a developmental abnormality. The speed of age-related cell loss in the substantia nigra (and other cell groups) has not been clearly established, but is probably not substantial.³⁹ An early life origin has been proposed in order to explain lifelong personality differences⁴⁰ and onset of disease as early as the third decade.²⁶ Probable lines of research should include a search for endogenous neurotoxins. Growth factors may also be involved and the antenatal period has been suggested as a potentially vulnerable time.⁴¹

We are grateful to Dr R O Barnard and Professor P L Lantos for pathological material for this study. Seventy-three brains were collected through the UK Parkinson's Disease Society Brain Bank. We thank Dr B H Anderton for kindly supplying a number of cytoskeletal monoclonal antibodies. W R G G was supported by a Medical Research Council Grant.

References

- Gibb WRG. The Lewy body and Parkinson's disease. In: Clifford Rose F, ed. *Parkinson's Disease: Clinical and Experimental Advances*. London: John Libbey and Co, 1987:3-11.
- Woodard JS. Concentric hyaline inclusion body formation in mental disease. Analysis of twenty-seven cases. *J Neuropathol Exp Neurol* 1962;21:442-9.
- Whitehouse PJ, Hedreen JC, White CL, Price DL. Basal forebrain neurons in the dementia of Parkinson disease. *Ann Neurol* 1983;13:243-8.
- Kosaka K, Yoshimura M, Ikeda K, Budka H. Diffuse type of Lewy body disease: progressive dementia with abundant cortical Lewy bodies and senile changes of varying degree—a new disease! *Clin Neuropathol* 1984;3:185-92.
- Oppenheimer D. Neuropathology of progressive autonomic failure. In: Bannister R, ed. *Autonomic failure*. Oxford University Press, London, 1983:267-83.
- Yokochi M, Narabayashi H, Iizuka R, Nagatsu T. Juvenile Parkinsonism—some clinical, pharmacological, and neuropathological aspects. *Adv Neurol* 1984;40:407-13.
- Sigwald J, Lapresle J, Raverdy P, Recondo NJ. Atrophie cérébelleuse familiale avec association de lésions nigériennes et spinales. *Presse Med* 1964;72:557-62.
- Sachdev HS, Forno LS, Kane CA. Joseph disease: a multisystem degenerative disorder of the nervous system. *Neurology* 1982;32:192-5.
- Dooling EC, Schoene WC, Richardson EP. Hallervorden-Spatz syndrome. *Arch Neurol* 1974;30:70-83.
- Agamanolis DP, Greenstein JI. Ataxia-telangiectasia. Report of a case with Lewy bodies and vascular abnormalities within cerebral tissue. *J Neuropathol Exp Neurol* 1979;38:475-89.
- Hirano A, Kurland LT, Sayre GP. Familial amyotrophic lateral sclerosis. A subgroup characterised by posterior and spinocerebellar tract involvement and hyaline inclusions in the anterior horn cells. *Arch Neurol* 1967;16:232-43.
- Bethlem J, den Hartog Jager WA. The incidence and characteristics of Lewy bodies in idiopathic paralysis agitans (Parkinson's disease). *J Neurol Neurosurg Psychiatry* 1960;23:74-80.
- Hunter S. The rostral mesencephalon in Parkinson's disease and Alzheimer's disease. *Acta Neuropathol* 1985;68:53-58.
- Qualman SJ, Haupt HM, Young P, Hamilton SR. Esophageal Lewy bodies associated with ganglion cell loss in achalasia. Similarity to Parkinson's disease. *Gastroenterology* 1984;87:848-56.
- Vogt C, Vogt O. Erkrankungen der Großhirnrinde im Lichte der Topistik, Pathoklise und Pathoarchitektur. *J Psychol Neurol* 1922;28:1-171.
- Duffy PE, Tennyson VM. Phase and electron microscopic observations of Lewy bodies and melanin granules in the substantia nigra and locus coeruleus in Parkinson's disease. *J Neuropathol Exp Neurol* 1965;24:398-414.
- Goldman JE, Yen S-H, Chiu F-C, Peress NS. Lewy bodies of Parkinson's disease contain neurofilament antigens. *Science* 1983;221:1082-4.
- Forno LS, Streifling AM, Sternberger LA, Sternberger NH, Eng LF. Immunocytochemical staining of neurofibrillary tangles and the periphery of Lewy bodies with a monoclonal antibody to neurofilaments. *J Neuropathol Exp Neurol* 1983;42:342.
- Dickson DW, Kress Y, Crowe A, Yen S-H. Monoclonal antibodies to Alzheimer neurofibrillary tangles. 2. Demonstration of a common antigenic determinant between ANT and neurofibrillary degeneration in progressive supranuclear palsy. *Am J Pathol* 1985;120:292-303.

- 20 Nakazato Y, Sasaki A, Hirato J, Ishida Y. Immunohistochemical localization of neurofilament protein in neuronal degenerations. *Acta Neuropathol* 1984; **64**:30-6.
- 21 Kahn J, Anderton BH, Gibb WRG, Lees AJ, Wells FR, Marsden CD. Neuronal filaments in Alzheimer's, Pick's and Parkinson's diseases. *N Engl J Med* 1985; **313**:520-1.
- 22 Kosaka K. Lewy bodies in cerebral cortex. Report of three cases. *Acta Neuropathol* 1978; **42**:127-34.
- 23 Wisniewski HM, Shek JW, Grua S, Sturman JA. Aluminium-induced neurofibrillary change in axons and dendrites. *Acta Neuropathol* 1985; **63**:190-97.
- 24 Burns RS, Markey SP, Phillips JM, Chiueh CC. The neurotoxicity of 1-methyl-4-phenyl-1,2,3,6-tetrahydropyridine in the monkey and man. *Can J Neurol Sci* 1984; **11**:166-8.
- 25 Forno LS, Langston JW, DeLanney LE, Irwin I, Ricaurte GA. Locus ceruleus lesions and eosinophilic inclusions in MPTP-treated monkeys. *Ann Neurol* 1986; **20**:449-55.
- 26 Bernheimer H, Birkmayer W, Hornykiewicz O, Jellinger K, Seitelberger F. Brain dopamine and the syndromes of Parkinson and Huntington. *J Neurol Sci* 1973; **20**:415-55.
- 27 Hornykiewicz O. Dopamine deficiency and dopamine substitution in Parkinson's disease. In: Winlow W, Markstein R, eds. *The Neurobiology of Dopamine Systems*. Manchester University Press, Manchester, 1986:321-28.
- 28 Beheim-Schwarzbach D. Über Zelleib-veränderungen im nucleus coeruleus bei Parkinsonian-symptomen. *J Nerv Ment Dis* 1952; **116**:619-32.
- 29 Hamada S, Ishii T. The Lewy body in the brain of the aged. *Adv Neurol Sci* 1963; **7**:184-6.
- 30 Hirai S. Ageing of the substantia nigra. *Adv Neurol Sci* 1968; **12**:845-9.
- 31 Forno LS, Alvard EC. The pathology of Parkinsonism. In: McDowell FH, Markham CH, eds. *Recent Advances in Parkinson's Disease*, Oxford: Blackwells, 1971:120-161.
- 32 Tomonaga M. Neuropathology of the locus coeruleus: a semiquantitative study. *J Neurol* 1983; **230**:231-40.
- 33 Mutch WJ, Dingwall-Fordyce I, Downie AW, Paterson JG, Roy SK. Parkinson's disease in a Scottish city. *Br Med J* 1986; **292**:534-6.
- 34 Rajput AH, Rozdilsky B, Hornykiewicz O, Shannak K, Lee T, Seeman P. Reversible drug-induced Parkinsonism. Clinicopathological study of two cases. *Arch Neurol* 1982; **39**:644-6.
- 35 Hassler R. Zur Pathologie der Paralysis agitans und des postenzephalitischen Parkinsonismus. *J Psychol Neurol* 1938; **48**:387-476.
- 36 Koller W, O'Hara R, Weiner W, et al. Relationship of aging to Parkinson's disease. In: Yahr MD, Bergmann KJ, eds. *Parkinson's Disease, Advances in Neurology*, vol 45. New York, Raven Press, 1987:317-21.
- 37 Calne DB, Langston JW. Aetiology of Parkinson's disease. *Lancet* 1983; **ii**:1457-59.
- 38 Ward CD, Duvoisin RC, Ince SE, Nutt JD, Eldridge R, Calne DB. Parkinson's disease in 69 pairs of twins and in a set of quadruplets. *Neurology* 1983; **33**:815-24.
- 39 Blin J, Agid Y. Nerve cell death in degenerative diseases of the central nervous system: clinical aspects. In Bock G, O'Connor M, eds. *Selective Neuronal Death*, Chichester, John Wiley, 1987:3-29.
- 40 Golbe LI, Cody RA, Duvoisin RC. Smoking and Parkinson's disease. Search for a dose-response relationship. *Arch Neurol* 1986; **43**:774-8.
- 41 Eldridge R, Ince SE. The low concordance rate for Parkinson's disease in twins: A possible explanation. *Neurology* 1984; **34**:1354-6.